





The use of smartphones in ophthalmology: technological development and application

O uso de smartphones na oftalmologia: desenvolvimento tecnológico e aplicação

José de Paula Barbosa Neto¹ , Bárbara de Araújo Lima Dutra² , Sarah Rubia Sales de Castro e Silva³ , João Crispim Moraes Lima Ribeiro⁴ 

1. Discente do curso de Medicina, Centro Universitario Christus (UNICHRISTUS), Fortaleza, CE, Brasil. 2. Fellowship em Segmento Anterior, Instituto Cearense de Oftalmologia, Fortaleza, CE. 3. Residente de Oftalmologia, Instituto Cearense de Oftalmologia, Fortaleza, CE. 4. Docente do curso de Medicina, Centro Universitario Christus (UNICHRISTUS), Fortaleza, CE, Brasil.

Abstract

Objective: Technological development has promoted several advances in society, including the creation of smartphones, which have been increasingly used in medicine, especially in ophthalmology. This study aimed to review the use of smartphones in ophthalmology. **Methods:** In January of 2020, the MEDLINE and LILACS databases were selected to provide articles containing the terms "Ophthalmology" and "Smartphone", filtering the results between the years of 2015 and 2019. The evaluated outcomes were finally included into the following categories in the discussion: "Visual acuity", "Amblyopia and strabismus", "Anterior segment", "Posterior segment", "Glaucoma", "Community patient education and assistance" and "Neurophthalmology". **Results:** Smartphones can be useful in several different areas of ophthalmology and can provide the patients better understating and adhesion to their treatment. **Conclusion:** Applications can be used as tools to facilitate the work of several professionals and improve the understanding of patients about their clinical conditions.

Keywords: Smartphones. Ophthalmology. Mobile Applications.

Resumo

Objetivo: O desenvolvimento tecnológico tem promovido diversos avanços na sociedade, incluindo a criação de smartphones, que têm sido cada vez mais utilizados na medicina, principalmente na oftalmologia. O objetivo deste estudo foi revisar o uso de smartphones na oftalmologia. **Métodos:** Durante o mês de janeiro de 2020, as bases de dados MEDLINE e LILACS foram selecionadas para buscar artigos contendo os termos "Oftalmologia" e "Smartphone", filtrando os resultados entre os anos de 2015 e 2019. Os dados avaliados foram, finalmente, incluídos nas seguintes categorias na discussão: "Acuidade visual", "Ambliopia e estrabismo", "Segmento anterior", "Segmento posterior", "Glaucoma", "Assistência e educação ao paciente da comunidade" e "Neurooftalmologia". **Resultados:** Os smartphones podem ser úteis em diversas áreas da oftalmologia e fornecem melhor compreensão e adesão dos pacientes ao tratamento. **Conclusão:** O uso de aplicativos pode ser utilizado como ferramenta para facilitar o trabalho de diversos profissionais e melhorar o entendimento dos pacientes sobre suas condições clínicas.

Palavras-chave: Smartphones. Oftalmologia. Aplicativos Móveis.

INTRODUCTION

Technological development has promoted several advances to society, such as the creation of smartphones, which are becoming increasingly common. It was estimated that in 2020, 70% of the world population will be using these gadgets¹. Among physicians, they can be used as tools of great practicality and efficiency, mainly with the use of applications, which, in 2013, were more than 19,000 related to the health area².

It is worth pointing out features of smartphones such as arrhythmia detection, 3D anatomical guides for surgeons, rheumatoid arthritis monitoring, and general utilities related to clinical practice: quick response to diagnostic results, prevention of medical errors, better management, and data accessibility, among others^{1,3,4,5}.

Concerning ophthalmology, there is a wide variety of uses

for these gadgets, promoting mechanisms to replace already established equipments or using mobile applications that offer new features for the devices. This study aims to review the use of smartphones in ophthalmology.

METHODS

We utilized the Medline (PubMed) and LILACS databases for all articles published between 2015 and 2019 to perform a systematic review of the literature. Descriptors included were "Smartphones" AND "Ophthalmology", intending to provide a general perspective of the smartphones and software applied to several ophthalmic conditions. Furthermore, we decided to include some works that we considered relevant to this review for further screening, as they brought relevant information notoriously in terms of apps.

Correspondence: João Crispim Moraes Lima Ribeiro. R. João Adolfo Gurgel, 133 - Cocó, Fortaleza - CE, 60190-180. E-mail: joaocrisp@gmail.com

Conflict of interest: The authors declare that there is no conflict of interest.

Received: 2020 Dec 12; Revised: 2021 Feb 15; 2021 May 12; Accepted: 2021 May 18

2 The use of smartphones in ophthalmology: technological development and application

Thus, in January 2020, four researchers independently analyzed the filtered data, according to a PRISMA protocol. Cross-sectional, cohort studies and case-control studies were included. Among the exclusion criteria were duplicates, review studies, unpublished articles, abstracts, theses, dissertations, book chapters, articles that did not use smartphones in ophthalmology, and articles considered not relevant to the subject matter. Abstracts considered interesting for the review were further evaluated. When considered to meet the criteria, the text was fully assessed and included in the final selection if approved.

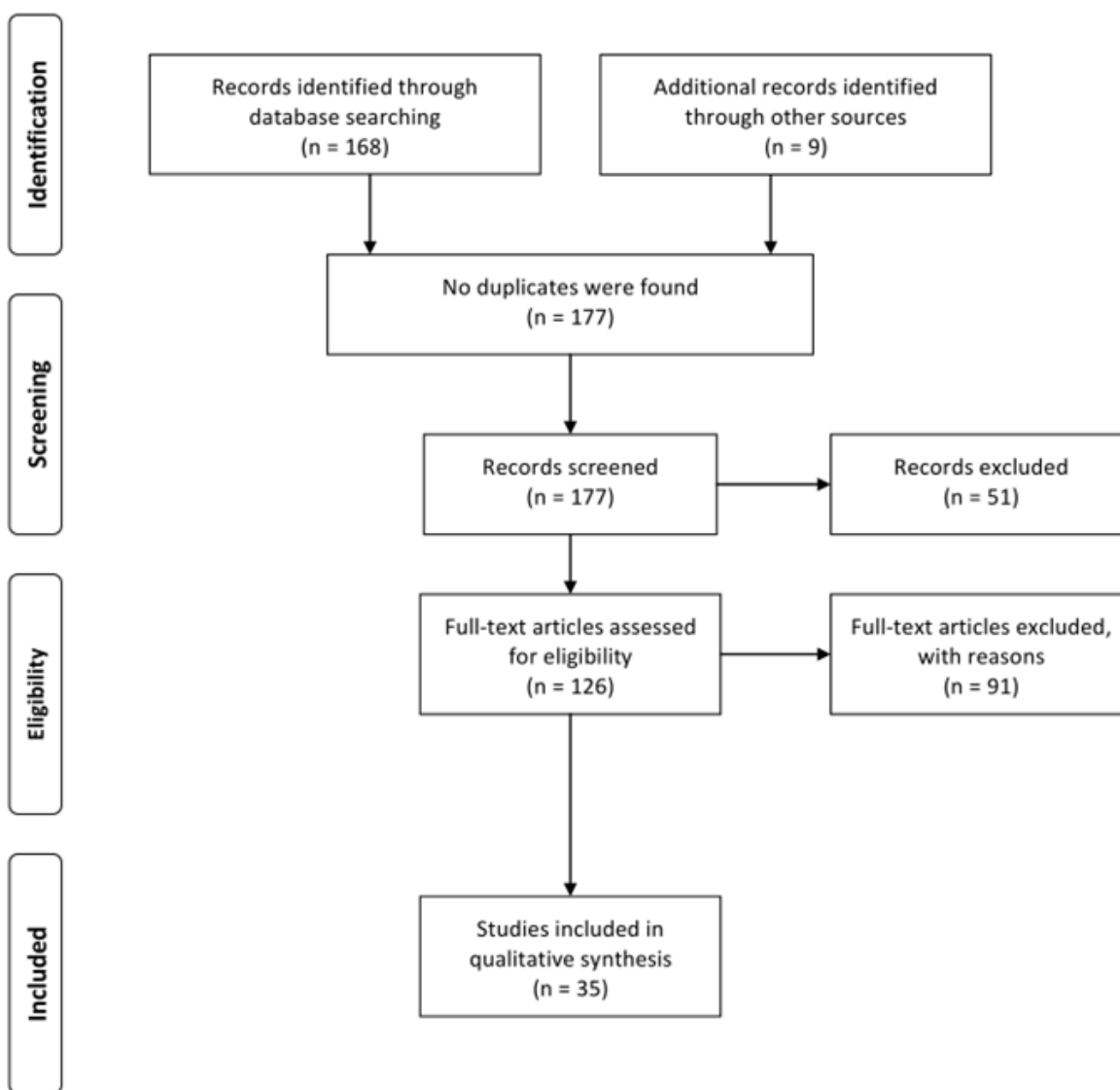
A reference list of the authors included was elaborated after extracting data from all the reviewers independently, including the major topic approached in each manuscript and the year of publication. The evaluated outcomes were finally included into the following categories in the discussion: "Visual acuity",

"Amblyopia and strabismus", "Anterior segment", "Posterior segment", "Glaucoma", "Community patient education and assistance" and "Neurophthalmology". This division was performed primordially based on the usability of smartphones among different ophthalmological specialties, but also including information related to the patient's educational experience and self-care.

RESULTS

During the years 2015 until 2019, 168 papers were found using the descriptors "Ophthalmology" and "Smartphones", and additional data included six articles. No duplicates were found, and after initial screening, 123 studies were eligible. In the final qualitative analysis, only 35 papers remained relevant to the subject matter (Figure 1).

Figure 1. PRISMA Flow Diagram.



Thus, information was obtained about various mobile applications, software, gadgets, and functionalities inherent to smartphones (Table 1).

Table 1. The main topics approached during the review containing articles that pointed relevant information among each group.

Main topic approached	Reference
Visual acuity	2016 O'Neil ⁸ 2019 Hogarty ⁹
Amblyopia and strabismus	2018 Peterseim ¹² 2018 Hashemi ¹⁰ 2018 Paudel ¹³
Eyelids and anterior segment	2014 Teichman ²³ 2016 Chen ¹⁹ 2016 Mohammadpour ¹⁴ 2017 Sanguansak ¹⁸ 2018 Pallas ²² 2019 Liu ¹⁵ 2019 Chandrakanth ¹⁶ 2019 Snyder ¹⁷ 2020 Dias ²⁰ 2020 Fernandes Dias ²¹
Posterior segment	2015 Adam ³¹ 2015 Ryan ³² 2016 Bastawrous ²⁴ 2016 Oluleye ²⁹ 2016 Micheletti ³⁰ 2016 Luwig ³³ 2016 Panwar ³⁴ 2017 Ademola-Popoola ²⁵ 2017 Furdova ²⁶ 2018 Elloumi ³⁵ 2019 Lekha ²⁷ 2019 Patel ²⁸
Glaucoma	2016 Russo ³⁶ 2016 Bastawrous ²⁴ 2016 Waisbourd ³⁹ 2018 Tsapakis ³⁸ 2019 Alawa ³⁷ 2016 Alhiali ⁴⁰ 2019 Rono ⁴¹ 2018 McAnany ⁴² 2019 Versek ⁴³

DISCUSSION

Visual acuity

Reductions in visual functioning are correlated with a reduction in health and well-being, particularly in the elderly^{6,7}. Visual acuity (VA) is the most common method of assessing visual function and is the gold standard for clinical trial results^{8,9}. Patients with detected reductions in VA are targets for additional clinical assessments and, when necessary, surgical interventions. Therefore, we must have an accurate and reproducible measure of VA.

In another study, O'Neill et al. recruited 60 participants and compared VA remotely using the Snellen table, Chart Pro (v1.3 on an Apple iPad 9.7 "), and the "Snellen" app (DrBloggsLtd v1.2 on an iPhone 4; brightness 50%) in a general practice consultation room. O'Neill found an average difference of less than one line between the physical graph and the APP with a high degree of correlation between the scores⁸.

There is currently insufficient evidence to recommend any VA measurement APP. This is partly due to confusion about the best control group to be used in studies (Snellen versus ETDRS) which, when associated with the wide variety of APP available, creates significant heterogeneity⁹.

Amblyopia and strabismus

Amblyopia is a developmental disorder in which there is a reduction in VA without detecting a structural cause^{10,11}. Amblyopia is caused due to the lack of clear stimuli in the retina (anisometropia or deprivation), or abnormal binocular interaction (strabismus) and is always secondary to another abnormality¹¹. The treatment essentially involves increasing the use of the amblyopic eye (traditionally done by tampon), as well as treating the cause.

Recently, research has investigated the potential utility of app for smartphones in the diagnosis and treatment of different aspects of amblyopia and related conditions. As strabismus is the main cause of amblyopia in children, developers have created an APP that helps identify strabismus or compensatory head positions, in addition to helping to monitor changes over time¹².

Peterseim et al. studied 206 participants and compared GoCheckKids vision screener software with the pediatric evaluation and found a sensitivity of 76.0 and specificity of 67.2% (15 false negatives) in detecting risk factors for amblyopia, indicating that an additional vision assessment would be necessary for these participants; furthermore, this study was limited by its small sample size¹².

Smartphone applications could be particularly useful for the assessment of strabismus as a proficient clinical method since the assessment requires a high degree of experience and

4 The use of smartphones in ophthalmology: technological development and application

observation skills and is often performed on uncooperative patients (young children)⁹.

It is possible that amblyopia can be effectively treated with the assistance of the amblyopia game app; however, it is essential that this happen with appropriate scientific validation. In addition, it is important that these softwares include recommendations that are implemented under appropriate medical supervision and monitoring, given the possible consequences for vision if mismanaged. These findings may demonstrate significant problems with the governance of medical app⁹. Although there is a significant number of apps aimed at the treatment of amblyopia, only a small portion has the collaboration of ophthalmologists or medical research groups¹³.

Anterior segment

The use of a smartphone in the evaluation of the previous segment allows health professionals and even patients themselves to easily prepare photographs and videos of the eye records when the slit lamp is not available or to facilitate the examination of the eye structures or the presence of foreign bodies in the anterior chamber¹⁴. There are also devices that allow smartphones to be attached semi-permanently to the slit lamp, reducing assembly time in the case of concomitant use of these devices¹⁵.

With a smartphone containing a camera of at least eight megapixels and with the aid of 10 to 90D lenses, it is possible to assess eyelids, medial and lateral cantus, conjunctiva, limbus, cornea, iris, and pupil, and with the 90D lenses it is possible to view the crypts of the iris¹⁴. It is also possible to obtain images from the anterior camera by attaching intraocular lenses to the smartphone's camera¹⁶.

High-resolution photos of the ocular surface can be saved and easily the professional has access to the status of the conjunctiva and cornea, which can be useful in ophthalmic care, including in the monitoring of patients who have been treated for trachoma^{14,17}.

In addition, anterior segment photos captured through adapters coupled to smartphones can be useful for managing patients after surgery¹⁸. When combined with visual acuity, intraocular pressure, and patient history, the images obtained can be acceptable in 93-100% of cases¹⁸.

The comparison between a smartphone (iPhone 5) and a camera (Canon EOS 10D) showed that the smartphone has good reproducibility. In low light the camera (Canon EOS 10D) for using a 22.7 mm x 15.1 mm CMOS sensor, demonstrating superior performance, compared to the iPhone 5 which uses a 4.54 mm x 3.42 mm CMOS sensor. With the iPhone's automatic ISO adjustment, backlit images benefit even in low light. The correlation between the two devices was moderate when evaluating nuclear opalescence, requiring more experience in

classifying cataract images, and was excellent when analyzing correlations of cortical and subcapsular cataracts¹⁹.

Applications, such as Eye Axis Check, can be used to capture and edit photographs of a protractor with 360° axis marking, being able to help in the preoperative and intraoperative toric intraocular lens alignment²⁰. This app can also be used to check the alignment of intrastromal corneal ring segments for keratoconus, presenting a fast learning curve and minimum differences in terms of axis compared to the marks made manually^{20,21}.

The toriCAM is another app designed to assess the alignment of the toric intraocular lens, presenting reductions in the mean error of the markings from $3.18^\circ \pm 2.22^\circ$ to $1.28^\circ \pm 1.34^\circ$ on both freehand and slit-lamp methods²².

It is also possible to evaluate the alignment of toric intraocular lens with a computer software, such as the ImageJ, by photographing images of the inserted lens and sending them to the software's platform, enabling a cost-effective and fast alternative to check the position of intraocular lens²³.

Posterior segment

The fundus evaluation is important for the diagnosis and monitoring of diseases, such as diabetic retinopathy, glaucoma, age-related macular degeneration, premature retinopathy, and systemic diseases such as hypertension, HIV / AIDS, and syphilis²⁴. Usually, direct or indirect ophthalmoscopy is used to evaluate the fundus, but high-cost equipment is required, which often has a low learning curve and limitations in the field of view²⁵. In addition, in some hospitals, for example, this examination is often not performed due to the absence of an ophthalmologist. As smartphones are more affordable, cheaper, and portable, their advanced technology in capturing images can be a good alternative^{25,26}.

The use of apps can be useful especially in young children, where it is not possible to obtain a good evaluation with indirect ophthalmoscopy. Beyond that smartphones are also useful in emergency cases, where the indirect ophthalmoscope may not be readily available and while screening retinopathy of prematurity, the main cause of childhood blindness, enabling the documentation and identification of severe forms of the disease in areas with little resource²⁷. Smartphones can also be useful for the diagnosis of other diseases in children, such as retinoblastoma, Coats' disease, commotion retinae, and optic nerve hypoplasia²⁸.

By attaching a 20D lens to a smartphone, it is possible to replicate the exam, generating a cheaper method for fundus analysis. In addition, it is possible to store images and send data, allowing the sharing of images²⁹. The smartphone camera can help physicians to monitor retinopathies, which can help to clarify the patient's condition and, consequently, improve adherence to the treatment.³⁰.

5 The use of smartphones in ophthalmology: technological development and application

Several studies indicate that the fundus examination performed using a smartphone shows similar results to those obtained by ophthalmoscopes¹⁹. This technique is especially useful in underdeveloped countries, which do not have a wide variety of technological resources^{26,29,30}. However, some studies show divergent results of sensitivity and specificity when comparing the smartphone with conventional methods of fundus evaluation^{31,32}.

There is also specialized equipment to facilitate this technique, such as the PexusScope, a portable device that can be easily attached to the smartphone, allowing a better analysis of the anterior and posterior segments³³. Other gadgets that help the fundus examination with the smartphone are iExaminer, Ocular CellScope, Portable Eye Examination Kit, and D-Eye System³⁴.

There are also methods that combine software on the computer with the use of the smartphone camera to assess more specific structures. Elloumi et al, through the combination of software and smartphone, developed a method for assessing the optic nerve head in patients with diabetic retinopathy, showing, in their study, good reliability and fast execution time³⁵.

The innovative role in research, education, and information sharing and the potential in ophthalmological practice is recognized, however, the use of a smartphone as a non-standardized diagnostic tool should be carefully considered²⁵.

Glaucoma

Visualization and interpretation of findings related to the optic nerve are essential in the ophthalmological examination. A study of 110 patients with ocular hypertension and open-angle glaucoma who had their cup-to-disc ratio analyzed by two glaucoma specialists demonstrated that ophthalmoscopy performed by a smartphone associated with a D-EYE adapter (D-EYE, Padova, Italy) did not present results that were statistically different from those presented by slit-lamp biomicroscopy, suggesting that the smartphone could be an alternative to this method³⁶.

Another study evaluated fundus photographs of non-clinicians who used an adapter called Peek Retina and a low-cost smartphone, obtaining images of the optic nerve in a pattern that allows its classification, comparing with images acquired through a camera operated by an ophthalmologist. This showed that the evaluation of the optical disc could be performed with the use of smartphones aided by this adapter²⁴. Thus; its great potential to help in the detection of preventable causes of blindness has been hypothesized²⁰. It was observed agreement between the images of the camera and the ones from Peek Retina, showing a high degree of confidence to measure a real change in the increase of the optic nerve excavation over time²⁴.

Although stereoscopic images are the preference in the evaluation and classification of the optic nerve, it has been shown that the images obtained with the smartphone camera do not

represent significant disadvantages in the classification of the probability of glaucoma²⁴. The smartphone ophthalmoscopy, considering its connectivity and portability, allows the benefit of this technology to be used in the screening of glaucoma, especially in environments with few resources, a place where the early detection of eye diseases is hampered due to the high cost and low portability of devices for fundoscopic evaluation²⁴. Devices are also being produced that enable visual field examinations with the use of smartphones aided by adapters, as well as virtual reality glasses, producing results similar to conventional examinations, which may suggest a more practical and economical alternative to assess glaucoma patients^{37,38}.

When assessing the interest in having the Glaucoma App, a glaucoma follow-up app with several functionalities, both patients and caregivers were pointed to be likely to download and use this type of APP, especially the ones who wore less than 65 years. However, the interest rates in the APP tended to be lower with the possibility of acquiring the app for 3\$ instead of downloading it for free³⁹.

Community patient education and assistance

The information given to the patient about his disease has a crucial impact on the process of understanding his clinical condition and prognosis. This is often essential for effective adherence to treatment, so patient-centered education is one of the pillars of medical intervention, thus some apps are developed to deepen patient's knowledge about his disease⁴⁰.

A study carried out in Saudi Arabia showed that although individual and group sessions were the main source of information about pathological conditions in ophthalmology; however mobile applications already represented a viable alternative to develop this knowledge, which can facilitate patient follow-up⁴⁰.

In addition, there are features that aim to facilitate the screening and referral system of patients with ophthalmic problems, such as the Peek Community Eye Health system, which includes the Peak Community Screening App, a tool that can be used by community agents to facilitate the screening of patients with the need for ophthalmological monitoring, also sending notifications of text messages to patients, generating letters of reference and showing the availability of services⁴¹.

Neurophthalmology

Pupillometry can be performed using the smartphone camera's infrared function, allowing the acquisition of results highly similar to those of the sensitometry⁴². In addition, there are devices under development that constitute faster and more practical methods for neurophthalmological explanations, such as the NeuroDotVR, a gadget with a smartphone and a headset that allow quantitative measurement of visual evoked potentials and local electric fields, allowing diagnostic and therapeutic stimuli, including several other features⁴³.

Strengths and limitations

This review shows a global overview of the utilities of smartphones in the diagnosis, treatment, and follow-up of many ophthalmic diseases, and also provides relevant aspects of these technologies in medical education and patient's comprehension of ocular conditions. However, although there are a significant number of APP related to ophthalmology, only a small percentage of those tools have been evaluated with a scientific approach, leading to a limited number of original manuscripts discussing the usability of specific apps.

Future perspectives

We believe that the use of medical apps is growing rapidly, leading to the development of new tools with innovative

functionalities, which can be useful to provide less expensive or more dynamic solutions for several activities, especially in ophthalmology. This can also represent a resource for the empowerment of self-care by patients, as the new technologies can be more accessible and intuitive. Thus, more studies might have to be developed to precisely assess the real impacts of these technological advances.

CONCLUSION

The growing use of smartphones around the world has transformed the health area in several aspects. In ophthalmology, the use of mobile applications, adapters, and cameras attached to smartphones have been facilitating the work and several professionals and the understanding of many patients about their respective diagnoses.

REFERENCES

1. Nguyen HH, Silva JN. Use of smartphone technology in cardiology. *Trends Cardiovasc Med*. 2016 May; 26(4):376-86. doi: 10.1016/j.tcm.2015.11.002.
2. Bavelloni A, Piazzini M, Raffini M, Faenza I, Blalock WL. Prohibitin 2: At a communications crossroads. *IUBMB Life*. 2015 Apr; 67(4): 239-54. doi: 10.1002/iub.1366.
3. Al-hadithy N, Ghosh S. Smartphones and the plastic surgeon. *J Plast Reconstr Aesthet Surg*. 2013 Jun; 66(6): e155-61. doi: 10.1016/j.bjps.2013.02.014.
4. Grainger R, Townsley H, White B, Langlotz T, Taylor WJ. Apps for People With Rheumatoid Arthritis to Monitor Their Disease Activity: A Review of Apps for Best Practice and Quality. *JMIR Mhealth Uhealth*. 2017 Feb; 5(2):e7. doi: 10.2196/mhealth.6956.
5. Patel RK, Sayers AE, Patrick NL, Hughes K, Armitage J, Hunter IA. A UK perspective on smartphone use amongst doctors within the surgical profession. *Ann Med Surg (Lond)*. 2015 Jun; 4(2): 107-112. doi: 10.1016/j.amsu.2015.03.004.
6. Dargent-Molina P, Favier F, Grandjean H, Baudoin C, Schott AM, Hausherr E, et al. Fall-related factors and risk of hip fracture: the EPIDOS prospective study. *Lancet*. 1996 Jul; 348(9021): 145-149. doi: 10.1016/s0140-6736(96)01440-7.
7. Lee PP, Spritzer K, Hays RD. The impact of blurred vision on functioning and well-being. *Ophthalmology*. 1997 Mar; 104(3): 390-396. doi: 10.1016/s0161-6420(97)30303-0.
8. O'Neill S, McAndrew DJ. The validity of visual acuity assessment using mobile technology devices in the primary care setting. *Aust Fam Physician*. 2016 Apr; 45(4): 212-215.
9. Hogarty DT, Hogarty JP, Hewitt AW. Smartphone use in ophthalmology: What is their place in clinical practice?. *Surv Ophthalmol*. 2020 Mar-Apr; 65(2): 250-262. doi: 10.1016/j.survophthal.2019.09.001.
10. Hashemi H, Pakzad R, Yekta A, Bostamzad P, Aghamirsalim M, Sardi S, et al. Global and regional estimates of prevalence of amblyopia: A systematic review and meta-analysis. *Strabismus*. 2018 Dec; 26(4): 168-183. doi: 10.1080/09273972.2018.1500618.
11. Holmes JM, Clarke MP. Amblyopia. *Lancet*. 2006 Apr; 367(9519): 1343-1351. doi: 10.1016/S0140-6736(06)68581-4.
12. Peterseim MMW, Rhodes RS, Patel RN, Wilson ME, Edmondson LE, Logan SA, et al. Effectiveness of the GoCheck Kids Vision Screener in Detecting Amblyopia Risk Factors. *Am J Ophthalmol*. 2018; 187: 87-91. doi: 10.1016/j.ajo.2017.12.020.
13. Paudel N. Smartphone Applications for Amblyopia Treatment: A Review of Current Apps and Professional Involvement. *Telemed J E Health*. 2018 Oct; 24(10): 797-802. doi: 10.1089/tmj.2017.0220.
14. Mohammadpour M, Mohammadpour L, Hassanzad M. Smartphone Assisted Slit Lamp Free Anterior Segment Imaging: A novel technique in teleophthalmology. *Cont Lens Anterior Eye*. 2016 Feb; 39(1): 80-1. doi: 10.1016/j.clae.2015.09.005.
15. Yen CH, Wang GQ, Lin TY, Liu CH. Semi-permanent smartphone adapter for microscopes: Design demonstration and workflow testing using a slit-lamp biomicroscope. *Taiwan J Ophthalmol*. 2019 Apr-Jun; 9(2): 111-117. doi: 10.4103/tjo.tjo_19_18.
16. Chandrakanth, P, Nallamuthu P. Anterior segment photography with intraocular lens. *Indian J Ophthalmol*. 2019 Oct; 67(10): 1690-1691. doi: 10.4103/ijo.IJO_52_19.
17. Snyder BM, Sié A, Tapsoba C, et al. Smartphone photography as a possible method of post-validation trachoma surveillance in resource-limited settings. *Int Health*. 2019 Nov; 11(6): 613-615. doi: 10.1093/inthealth/ihz035.
18. Sanguansak T, Morley K, Morley M, Kusakul S, Lee R, Shieh E, et al. Comparing smartphone camera adapters in imaging post-operative cataract patients. *J Telemed Telecare*. 2017 Jan; 23(1): 36-43. doi: 10.1177/1357633X15625400.
19. Chen DZ, Tan CW. Smartphone Imaging in Ophthalmology: A Comparison with Traditional Methods on the Reproducibility and Usability for Anterior Segment Imaging. *Ann Acad Med Singap*. 2016 Jan; 45(1):6-11.
20. Dias FAF, Dias VJF, Dutra B de AL, Marques ACS, Marçal E, Lucena A da R, Crispim Ribeiro J. Mobile App for Pre- and Intraoperative Assessment of Astigmatism Correction with Toric Intraocular Lenses in Cataract Surgery. *Journal of Ophthalmology*. 2020 Mar 23;2020:1-7. doi: 10.1155/2020/8354140.
21. Dias FAF, Dias VJF, Carneiro CLB, Bernardes BG, Dutra BAL, Ribeiro JC. A Novel Mobile Application for Preoperative and Intraoperative Assessments of Intrastromal Corneal Ring Segments Implantation for Keratoconus. *Cornea*. 2020 Sep; 39(9):1132-8. doi: 10.1097/ICO.0000000000002385.
22. Pallas A, Yeo TK, Trevenen M, Barrett G. Evaluation of the Accuracy of Two Marking Methods and the Novel toriCAM Application for Toric Intraocular Lens Alignment. *J Refract Surg*. 2018; 34(3): 150-155. doi: 10.3928/1081597X-20180115-03.
23. Teichman JC, Baig K, Ahmed II. Simple technique to measure toric intraocular lens alignment and stability using a smartphone. *J Cataract Refract Surg*. 2014 Dec; 40(12): 1949-52. doi: 10.1016/j.jcrs.2014.09.029.
24. Bastawrous A, Giardini ME, Bolster NM, Peto T, Shah N, Livingstone

7 The use of smartphones in ophthalmology: technological development and application

- IAT, et al. Clinical Validation of a Smartphone-Based Adapter for Optic Disc Imaging in Kenya. *JAMA Ophthalmol.* 2016 Feb; 134(2): 151-8. doi: 10.1001/jamaophthalmol.2015.4625.
25. Ademola-Popoola DS, Olatunji VA. Retinal imaging with smartphone. *Niger J Clin Pract.* 2017 Mar; 20(3): 341-345. doi: 10.4103/1119-3077.201428.
26. Furdova A, Furdova A, Krcmery V. Our experience with smartphone and spherical lens for the eye fundus examination during humanitarian project in Africa. *Int J Ophthalmol.* 2017 Jan; 10(1):157-160. doi: 10.18240/ijo.2017.01.25.
27. Lekha T, Ramesh S, Sharma A, Abinaya G. MII RetCam assisted smartphone based fundus imaging for retinopathy of prematurity. *Indian J Ophthalmol.* 2019 Jun; 67(6): 834-9. doi: 10.4103/ijo.IJO_268_19
28. Patel TP, Kim TN, Yu G, Dedania VS, Lieu P, Qian CX, et al. Smartphone-Based, Rapid, Wide-Field Fundus Photography for Diagnosis of Pediatric Retinal Diseases. *Transl Vis Sci Technol.* 2019 May; 8(3): 29. doi: 10.1167/tvst.8.3.29.
29. Oluleye TS, Rotimi-Samuel A, Adenekan A. Mobile phones for retinopathy of prematurity screening in Lagos, Nigeria, sub-Saharan Africa. *Eur J Ophthalmol.* 2016 Jan-Feb; 26(1): 92-94. doi: 10.5301/ejo.5000666.
30. Micheletti JM, Hendrick AM, Khan FN, Ziemer DC, Pasquel FJ. Current and Next Generation Portable Screening Devices for Diabetic Retinopathy. *J Diabetes Sci Technol.* 2016 Feb;10(2): 295-300. doi: 10.1177/1932296816629158.
31. Adam MK, Brady CJ, Flowers AM, Juhn AT, Hsu J, Garg SJ, et al. Quality and Diagnostic Utility of Mydriatic Smartphone Photography: The Smartphone Ophthalmoscopy Reliability Trial. *Ophthalmic Surg Lasers Imaging Retina.* 2015 Jun; 46(6): 631-7. doi: 10.3928/23258160-20150610-06.
32. Ryan ME, Rajalakshmi R, Prathiba V, Anjana RM, Ranjani H, Narayan KMV, et al. Comparison Among Methods of Retinopathy Assessment (CAMRA) Study: Smartphone, Nonmydriatic, and Mydriatic Photography. *Ophthalmology.* 2015 Oct;122(10): 2038-43. doi: 10.1016/j.ophtha.2015.06.011.
33. Ludwig CA, Murthy SI, Pappuru RR, Jais A, Myung DJ, Chang RT. A novel smartphone ophthalmic imaging adapter: User feasibility studies in Hyderabad, India. *Indian J Ophthalmol.* 2016 Mar; 64(3):191-200. doi: 10.4103/0301-4738.181742.
34. Panwar N, Huang P, Lee J, Keane PA, Chuan TS, Richhariya A, et al. Fundus Photography in the 21st Century-- A Review of Recent Technological Advances and Their Implications for Worldwide Healthcare. *Telemed J E Health.* 2016 Mar; 22(3):198-208. doi: 10.1089/tmj.2015.0068.
35. Elloumi Y, Akil M, Kehtarnavaz N. A mobile computeraided system for optic nerve head detection. *Computer Methods Programs Biomed.* 2018 Aug; 162: 139-48. doi: 10.1016/j.cmpb.2018.05.004.
36. Russo A, Mapham W, Turano R, Costagliola C, Morescalchi F, Scaroni N, et al. Comparison of Smartphone Ophthalmoscopy With Slit-Lamp Biomicroscopy for Grading Vertical Cup-to-Disc Ratio. *J Glaucoma.* 2016 Sep; 25(9): e777-81. doi: 10.1097/IJG.0000000000000499.
37. Alawa KA, Nolan RP, Han E, Arboleda A, Durkee H, Sayed MS, et al. Low-cost, smartphone-based frequency doubling technology visual field testing using a head-mounted display. *Br J Ophthalmol.* 2021 Mar; 105(3): 440-444. doi: 10.1136/bjophthalmol-2019-314031.
38. Tsapakis S, Papaconstantinou D, Diagourtas A, Kandarakis S, Droustas K, Andreanos K, Brouzas D. Home-based visual field test for glaucoma screening comparison with Humphrey perimeter. *Clin Ophthalmol.* 2018;12:2597-2606.
39. Waisbourd M, Dhimi H, Zhou C, Hsieh M, Abichandani P, Pro MJ, et al. The Wills eye glaucoma app: Interest of patients and their caregivers in a smartphone-based and tablet-based glaucoma application. *J Glaucoma.* 2016 Sep; 25(9): e787-91. doi: 10.1097/IJG.0000000000000504.
40. Alhilali SM, Almuammar AM, Alkahtani E, Khandekar R, Aljasser AA. Preferred Method of Education Among Patients in Ophthalmic Care in Saudi Arabia. *Middle East Afr J Ophthalmol.* 2016 Apr-Jun; 23(2):168-71. doi: 10.4103/0974-9233.171780.
41. Rono H, Bastawrous A, Macleod D, Wanjala E, Gichuhi S, Burton M. Peek Community Eye Health - mHealth system to increase access and efficiency of eye health services in Trans Nzoia County, Kenya: study protocol for a cluster randomised controlled trial. *Trials.* 2019 Aug; 20(1): 502. doi: 10.1186/s13063-019-3615-x.
42. McAnany JJ, Smith BM, Garland A, Kagen SL. iPhone-based Pupillometry. *Optom Vis Sci.* 2018 Oct; 95(10): 953-8. doi: 10.1097/OPX.0000000000001289.
43. Versek C, Rissmiller A, Tran A, Taya M, Chowdhury K, Bex P, et al. Portable System for Neuro-Optical Diagnostics Using Virtual Reality Display. *Mil Med.* 2019 Mar; 184(Suppl 1): 584-92. doi: 10.1093/milmed/usy286.

Como citar este artigo/ How to cite this article:

Barbosa JP Neto, Dutra BAL, Silva SRC, Ribeiro JCL. The use of smartphones in ophthalmology: technological development and application. *J Health Biol Sci.* 2021; 9(1):1-7.