

# Silicone-induced granuloma, hypercalcemia and chronic kidney disease in a transgender patient

## Granuloma induzido por silicone, hipercalcemia e doença renal crônica em um paciente transgênero

Tattieri Alenninne Cardoso Barros<sup>1</sup> , José Narciso Júnior<sup>1</sup> , Aline Cunha Lima Alcântara<sup>1</sup> , Rafael Siqueira Athayde Lima<sup>1</sup>   
Geraldo Bezerra da Silva Junior<sup>2</sup> 

1. Hospital Universitário Walter Cantídio (EBSERH), Fortaleza, CE, Brazil. 2. Curso de Medicina, Centro de Ciências da Saúde, Universidade de Fortaleza, Fortaleza, CE, Brazil.

### Abstract

**Background:** hypercalcemia mediated by a silicone-induced granulomatous reaction is a condition that, despite being rare, must be remembered since there is an increasing demand for aesthetic procedures among the general population. It is necessary to rule out other causes of hypercalcemia, such as hyperparathyroidism, hypercalcemia of malignancy, infectious and non-infectious granulomatous diseases, as well as the use of drugs. **Case presentation:** We present a patient with a history of large amounts of silicone implants who was admitted to a hospital presenting hypercalcemia and chronic kidney disease. A skin biopsy revealed a granulomatous foreign body reaction associated with exogenous siliconomatous material. Treatment with corticosteroids was initiated, with partial renal function improvement, with no renal replacement therapy needed. **Conclusion:** Patients with silicone implants should be carefully monitored for renal function and may be informed to avoid nephrotoxic agents as there is sufficient evidence that this type of aesthetic procedure can trigger hypercalcemia and CKD.

**Keywords:** hypercalcemia; granuloma; silicone.

### Resumo

**Introdução:** a hipercalcemia mediada por uma reação granulomatosa induzida por silicone é uma condição que, apesar de rara, deve ser lembrada, pois há uma demanda crescente por procedimentos estéticos na população em geral. É necessário descartar outras causas de hipercalcemia, como hiperparatireoidismo, hipercalcemia da malignidade, doenças granulomatosas infecciosas e não infecciosas, bem como o uso de medicamentos. **Relato de caso:** apresentamos um paciente com histórico implante de grandes quantidades de silicone, que foi admitido em um hospital apresentando hipercalcemia e doença renal crônica (DRC). A biópsia de pele revelou reação granulomatosa tipo corpo estranho associada a material siliconomatoso exógeno. Foi iniciado tratamento com corticosteroides, com melhora parcial da função renal, sem necessidade de terapia renal substitutiva. **Conclusão:** os pacientes com implantes de silicone devem ser cuidadosamente monitorados quanto à função renal e devem ser informados para evitar agentes nefrotóxicos, pois há evidências suficientes de que esse tipo de procedimento estético pode desencadear hipercalcemia e DRC.

**Palavras-Chave:** hipercalcemia; granuloma; silicone.

### INTRODUCTION

Industrial silicone-based fillers for aesthetic purposes have become increasingly common around the world<sup>1,2</sup>. Moreover, patients are often not warned about the risks inherent to these procedures, which are often carried out indiscriminately. Hypercalcemia is a complication of silicone implants that occurs due to a granulomatous foreign body reaction and may cause chronic kidney disease (CKD)<sup>3,4,5</sup>.

We describe the case of a transgender female exposed to a large amount of siliconomatous material injection, developing a granulomatous reaction associated with hypercalcemia and CKD.

### CASE REPORT

A 35-year-old transgender female was admitted to a tertiary

hospital to undergo cranioplasty for a brain hernia due to cranioencephalic traumatism (physical aggression), which happened four (4) years before. She reported abusing non-steroidal anti-inflammatory drugs (NSAIDs) for headaches. She denied the use of other medications, anabolic steroids, or vitamin D supplements. She noted only one (1) urinary tract infection (UTI), treated with antibiotic-guided therapy by her assistant physician. Additionally, she reported several industrial silicone injections ten (10) years into her breasts, buttocks, hips, and lower limbs, totaling about 12 liters of silicone. Upon admission, her blood pressure was 120 x 85 mmHg, her heart rate was 90 bpm, and her temperature was 36,3°C. Physical examination was unremarkable. The serum laboratory tests revealed creatinine (sCr) 5.3 mg/dl, eGFR 10ml/min/1.73m<sup>2</sup> (estimated for transgender patients), urea 95 mg/dl, potassium 3.8 meq/l, sodium 139 meq/l, chloride 113 meq/l, bicarbonate

**Correspondence:** Tattieri Alenninne Cardoso Barros R. Antero Coelho, 47, Fortaleza, Ceará, Brazil. Email: tattieri@edu.unifor.br

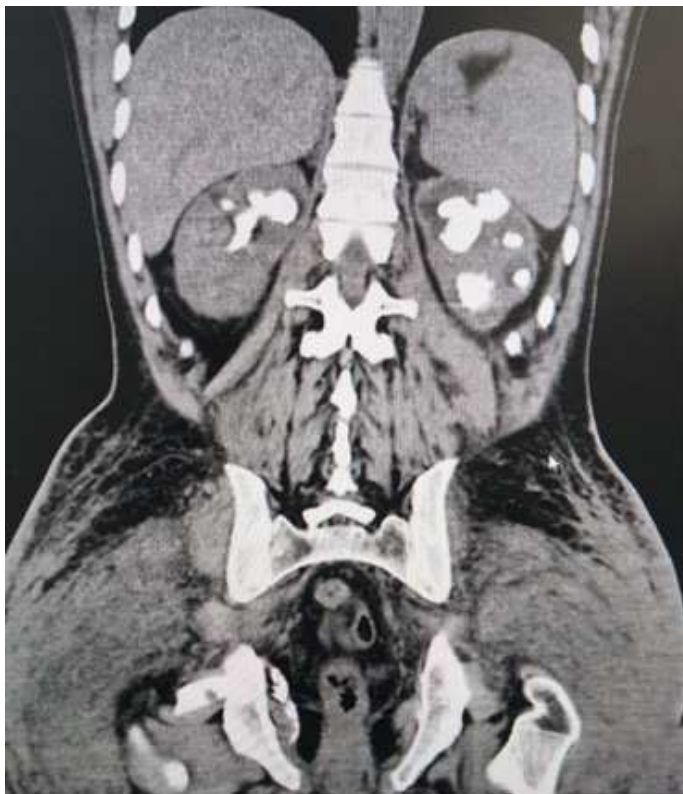**Conflict of interest:** There is no conflict of interest on the part of any of the authors.

Received: 2024 Jun 4; Revised: 2024 Jun 21; Accepted: 2024 Jun 25

## 2 Hipercalcemia secundária a granuloma por injeção de silicone

13 mmol/l, ionic calcium 1.54 mmol/l, total calcium 11 mg/dl, albumin 3.3 mg/dl, intact parathyroid hormone (iPTH) < 3 pg/ml, 25-hydroxyvitamin D 18 ng/ml, phosphorus 5.8 mg/dl, alkaline phosphatase 168 U/L. The HIV, hepatitis B, and hepatitis C serology were negative, and serum protein electrophoresis was normal. The urine test revealed a density of 1008, pH 6.5, traces of protein, five (5) red blood cells per field, numerous leukocytes, and no bacteria. The abdominal tomography showed bilateral staghorn calculi hip silicone material. (figure 1). The static and dynamic renal scintigraphy

**Figure 1.** Abdominal/pelvis CT showing bilateral staghorn calculus and hip silicone material.



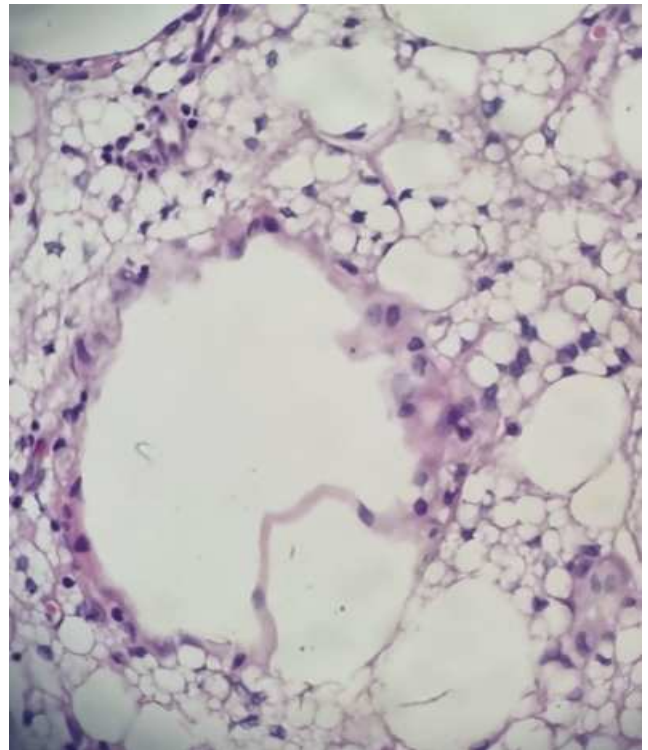
### DISCUSSION

Approximately 8.5 million cosmetic procedures with injectable fillers were performed worldwide in 2017<sup>6</sup>. In this regard, hypercalcemia secondary to the granulomatous reaction caused by industrial silicone is presenting increasing frequency, along with aesthetic silicone procedures. It is estimated that foreign body granulomas associated with cosmetic injections may occur in up to 1% of cases and may rarely trigger calcitriol-mediated hypercalcemia<sup>6</sup>. The case presented here highlights a rare and severe complication of silicone use, with the most probable cause of CKD being hypercalcemia induced by a granulomatous reaction.

Hypercalcemia is a disorder characterized by corrected serum calcium levels above 10.5 mg/dL. In more than 90% of cases, they are related to hyperparathyroidism or neoplasms but can also be due to infectious granulomatous diseases, such as histoplasmosis, tuberculosis, and leprosy,

revealed highly decreased glomerular function in the left kidney and a moderate depressed degree in the right kidney. The relative tubular function in the left kidney was 28.8%, and 71.2% in the right kidney. A skin biopsy was performed and showed a granulomatous foreign body reaction associated with exogenous siliconomatous material. She was treated with corticosteroid (prednisone 30 mg per day for four (4) weeks and presented improvement in renal function. She was discharged from the hospital with sCr 3 mg/dL (eGFR 20ml/min/1.73m<sup>2</sup>) and total calcium 9.3 mg/dl.

**Figure 2.** Photomicrograph at 200 times magnification, hematoxylin and eosin staining, author's own source. Histological sections show a vacuole with a lipidized and siliconomatous appearance permeated by xantomized macrophage cells.



as well as non-infectious granulomatous diseases, such as sarcoidosis, eosinophilic granulomatosis with polyangiitis and granulomatosis with polyangiitis<sup>7</sup>, which were all discarded in the studied case.

The associated mechanism of granulomatous diseases-induced hypercalcemia is increased expression of the enzyme 1 alpha-hydroxylase (also known as cytochrome p450 27B1 or CYP27B1) generated by the granuloma. This enzyme is present in renal tubular cells but can also be found in other extrarenal sites, including immune cells, involved in granulomatous diseases, such as alveolar macrophages from patients with sarcoidosis.<sup>8</sup> Therefore, 1 alpha-hydroxylase leads to greater conversion of 25-hydroxyvitamin D into 1,25-dihydroxyvitamin D and consequently increases serum calcium due to intestinal absorption and bone reabsorption<sup>8</sup>.

### 3 Hipercalcemia secundária a granuloma por injeção de silicone

In addition, hypercalcemia in silicone granulomas can also occur through increasing prostaglandin production. Macrophages in granulomas are loaded with silicone particles, which stimulate arachidonic acid metabolism that results in the synthesis of prostaglandins<sup>9</sup>.

In the present case, we found PTH-independent hypercalcemia, decreased kidney function, and nephrolithiasis. Skin biopsy confirmed granuloma-mediated hypercalcemia. Depending on the extent and location of the silicone implants, surgical resection of the siliconomatous material may be needed. However, in the aforementioned case, surgery was not an option because of the large quantity of silicone, around 10 liters, and the extent of the disease. Therefore, she was treated with corticosteroids in addition to the urological procedures, allowing her to be discharged without renal replacement therapy need.

Another important aspect to note is the specific transgender

health issues<sup>10</sup>, which can still be considered poorly studied. Kidney disease among transgender people has been described before<sup>11,12</sup>, and risk factors include hormone replacement (mainly testosterone, which increases blood pressure, and estradiol, predisposing to thromboembolism). In the present case, silicone implants were considered the main cause of hypercalcemia and subsequent CKD. However, there was also NSAID use, which is a known risk factor for CKD<sup>13</sup> and could have contributed to kidney function loss in this case.

Finally, we recommend that patients with silicone implants be carefully monitored for renal function, also adopting preventive measures since the first implant, including adequate hydration, avoidance of NSAIDs or other nephrotoxic agents, blood pressure control, and healthy lifestyle, as there is sufficient scientific evidence that this type of aesthetic procedure can trigger a granulomatous reaction, which can lead to hypercalcemia and CKD.

## REFERENCES

1. Ivanova EV, Minyaylo EO, Temnikov MN, Mukhtorov LG, Atroshchenko YM. Silicones in Cosmetics. *Polym. Sci. Ser. B.* 2023; 65: 578–594. doi: <https://doi.org/10.1134/S1560090423600201>.
2. Powell SK, Cruz RLJ, Ross MT, Woodruff MA. Past, Present, and Future of Soft-Tissue Prosthetics: Advanced Polymers and Advanced Manufacturing. *Adv Mater.* 2020 Oct; 32(42): e2001122. doi: 10.1002/adma.202001122.
3. Dangol GMS, Negrete H. Silicone-Induced Granulomatous Reaction Causing Severe Hypercalcemia: Case Report and Literature Review. *Case Rep Nephrol.* 2019 Jan; 2019: 9126172.
4. Barilaro G, Spaziani Testa C, Cacciani A, Donato G, Dimko M, Mariotti A. ASIA syndrome, calcinosis cutis and chronic kidney disease following silicone injections. A case-based review. *Immunol Res.* 2016 Dec; 64(5-6):1142-1149. doi: 10.1007/s12026-016-8871-1.
5. Yedla N, Perez E, Lagari V, Ayala A. Silicone granulomatous inflammation resulting in hypercalcemia: a review of the literature. *AACE Clin Case Rep.* 2019 Mar-Apr; 5(2): e119-e123. doi: 10.4158/ACCR-2018-0277.
6. Manfro AG, Lutzky M, Dora JM, Kalil MA, Manfro RC. Case reports of hypercalcemia and chronic renal disease due to cosmetic injections of polymethylmethacrylate (PMMA). *Braz J Nephrol.* 2021 Apr-Jun; 43(2): 288–92. doi: <https://doi.org/10.1590/2175-8239-JBN-2020-0044>.
7. Tonon CR, Silva TA, Pereira FW, Queiroz DA, Favero EL Junior, Martins D, Azevedo OS, et al. A Review of Current Clinical Concepts in the Pathophysiology, Etiology, Diagnosis, and Management of Hypercalcemia. *Med Sci Monit.* 2022 Feb; 28: e935821. doi: 10.12659/MSM.935821. PMID: 35217631; PMCID: PMC8889795.
8. Visnyei K, Samuel M, Heacock L, Cortes JA. Hypercalcemia in a male-to-female transgender patient after body contouring injections: a case report. *J Med Case Rep.* 2014 Feb; 8: 71. doi: 10.1186/1752-1947-8-71. PMID: 24572248; PMCID: PMC3976093.
9. Edwards BJ, Saraykar S, Sun M, Murphy WA Jr, Lin P, Gagel R. Resection of granulomatous tissue resolves silicone induced hypercalcemia. *Bone Rep.* 2016 Dec; 5:163-167. doi: 10.1016/j.bonr.2015.07.001. PMID: 28580383; PMCID: PMC5440967.
10. Safer JD, Tangpricha V. Care of the Transgender Patient. *Ann Intern Med.* 2019 Jul 2;171(1): ITC1-ITC16. doi: 10.7326/AITC201907020.
11. Guedes IS, Vasconcelos LV, Oliveira AP, Daher EF, Silva GB Junior. [Controversy in estimating glomerular filtration rate through traditional equations in transgender people: discussion through a case report]. *G Ital Nefrol.* 2022 Aug; 39(4): 2022-vol4.
12. Collister D, Krakowsky Y, Potter E, Millar AC. Chronic Kidney Disease in the Transgender, Nonbinary, or Gender Diverse Person. *Semin Nephrol.* 2022 Mar; 42(2): 129-141. doi: 10.1016/j.semnephrol.2022.04.004.
13. Lucas GN, Leitão AC, Alencar RL, Xavier RM, Daher EF, Silva GB Junior. Pathophysiological aspects of nephropathy caused by non-steroidal anti-inflammatory drugs. *J Bras Nefrol.* 2019 Jan-Mar; 41(1): 124-130. doi: 10.1590/2175-8239-JBN-2018-0107.

### How to cite this article/ Como citar este artigo:

Barros TA, Narciso J Júnior, Alcântara AC, Lima RS, Silva GB Junior. Silicone-induced granuloma, hypercalcemia and chronic kidney disease in a transgender patient. *J Health Biol Sci.* 2024; 12(1):1-3.